European Review for Medical and Pharmacological Sciences 2022; 26: 8713-8718

Association of monomeric C-Reactive Protein (m-CRP) with hypothalamic neurons after CRP hippo-campal administration in a model of dementia

R.S. AL-BARADIE[1], A. ABDEL-HADI[1], F. AHMAD[2], S.A. ALSAGABY[1], M. SLEVIN[3], W. ALTURAIKI[1], Y. MADKHALI[1], B.M. ALJARALLAH[4], M. ALQAHTANI[5], M. MIRAJ[2], I. AHMAD[6], N. ALBARADIE[7], R. ALBARADIE[7]

[1]Department of Medical Laboratory Sciences, [2]Department of Physical Therapy and Health Rehabilitation, College of Applied Medical Sciences, Majmaah University, Majmaah, Saudi Arabia
[3]School of Life Sciences, Manchester Metropolitan University, Manchester, UK
[4]Department of Medicine, Qassim University Medical City, Al Qassim, Saudi Arabia
[5]College of Applied Sciences, Almareefa University, Dariyah, Riyadh, KSA
[6]Department of Medical Rehabilitation Sciences, College of Applied Medical Sciences, King Khalid University, Saudi Arabia
[7]College of Medicine, Majmaah University, Majmaah, Saudi Arabia

Abstract. – OBJECTIVE: The ensuing ischemia due to the disruption of blood supply to the brain is one of the most common causes of stroke. Evidence suggests a clear association of the ischemic injury with vascular dementia and Alzheimer's disease (AD). In response to the brain ischemia, a cascade reaction starts leading to neuronal damage due to oxidative stress and other inflammatory mediators. A pilot study was done, which showed that following stroke, monomeric-C-reactive protein (mCRP) is expressed in large quantities around the infarcted zone and this CRP is able to induce neurodegeneration and inflammation potentially perpetuating dementia.

MATERIALS AND METHODS: We examined both patient brain samples and excised mouse brain tissue, previously injected with 1.75 mg/mL mCRP into the CA1 area of the hippocampus through the stereotactic surgical procedures and followed them over a period of over 6 months. The distribution of mCRP was examined through immunohistochemistry (mouse anti-human mCRP-specific antibodies 8C10).

RESULTS: We observed a novel finding: those micro vessels close to the injection location were strongly stained with mCRP only in the mice that had been injected with mCRP, indicating that this small blood vessel can spread it throughout the brain.

CONCLUSIONS: mCRP found in the brain after a hemorrhagic stroke promotes damage over a large area via the induction of inflammation and degeneration of perivascular compartments.

Key Words:
Hypothalamic neurons, Monomeric-C-reactive protein (mCRP), Neurodegeneration and inflammation, Model of dementia, Vascular dementia.

Introduction

There are significant mortality and morbidity rates associated with intracranial hemorrhage (ICH) because of the multiple complications that may emerge. Monomeric-C-reactive protein is the biologically active form of the native CRP molecule produced in large quantities during tissue damage and inflammation[1]. The implication of mCRP in inflammation has been established over the last few years, most recently, with Thiele et al[2] showing that renal ischemia-reperfusion injury in rats associated with inflammation could be blocked effectively using an inhibitor of native pentameric CRP dissociation [1,6-bis(phosphocholine)-hexane]. We previously showed[1] its importance in stroke pathophysiology and its ability to directly stimulate phosphorylation of Tau, a critical molecule associated with dementia. More than 50% of people suffer from dementia within a year after developing moderate to severe stroke and mCRP secretion is one of the factors causing brain tissue dysfunction and degeneration[2].

Corresponding Author: Raid S. Al-Baradie, MD; e-mail: r.albaradie@mu.edu.sa

Tissue damage or inflammation makes the native CRP converting to mCRP, which is the biologically active form of the molecule. This molecule has been linked to dementia because of its role in stroke pathophysiology and its ability to directly stimulate Tau-phosphorylation. Stroke survivors are twice as likely to develop dementia within a year from their stroke, and mCRP production is one factor contributing to brain tissue degeneration and dysfunction.

The capability of mCRP to be 'laid down' in tissue after stroke and to become expressed in regions distant to the injury site is fascinating and could explain disability and damage within non-directly affected sites of the brain. Following on from our full biological characterization of mCRP structure and function in neurological conditions[1], we performed a detailed ICH structural and localization analysis.

Recent studies[3-5] have shown the presence of mCRP in the core and penumbral region of the infarcted brain in stroke patients. The evidence establishes a clear relationship between the accumulation of mCRP revascularization in peri-infarcted regions of stroke patients. In addition, we demonstrated that where the patient had co-morbidity and evidence of Alzheimer's like plaques, mCRP seemed to co-localize with neuritic plaques and more developed Aβ plaques whilst normal looking tissue was negatively stained (Figure 1)[5].

The objective of this study is to identify the localization of mCRP in the hypothalamus after direct intra-hippocampal injection. To see any other associated features of mCRP-positive tissue and staining linking to endothelial cells, neurons, and inflammatory macrophages/immune cells.

Materials and Methods

Eleven archived brain tissue blocks, which contained both lesioned and non-lesioned regions from stroke patients and age-matched controls, were selected for further examination. Necropsy was conducted after death due to subsequent lesions, edema, and brain herniation or cardiovascular arrhythmia.

General neuropathological investigation at necropsy indicated encephalomalacia, pericapillary bleeding, or ventricular blood inundation in more recent lesions, yellowish gliotic regions, and cavitation in organized lesions. Microscopically, ischemic lesions were distinguished by the presence of neuronal eosinophilia, while hemorrhagic lesions were distinguished by the presence of mild vasculitis, petechial or massive hemorrhages, and perilesional cortical vacuolation.

After antigen retrieval, a double immunofluorescence procedure was carried out. Sections were allowed to cool to room temperature and stored in a 2% hydrogen peroxide solution for 30 minutes after antigen retrieval in 0.01 M sodium citrate buffer, pH 6, heated to 95°C. Then it had been incubated for 18 hours at 4°C with the GFAP antibodies (1:50 in 1% goat serum/0.1% Tween 20/1xPBS). After this, it was again incubated for another 18 hours with rabbit anti-aquaporin 4 at 4°C.

Using a mixture of goat anti-rabbit CFL 488 and anti-mouse CFL 568 (1:100, Santa Cruz, Heidelberg, Germany) in 1% Goat serum/0.1% Tween 20/1xPBS for 4 hours at RT, antigens were identified the following day. A combination of anti-mouse mCRP and anti-rabbit aquaporin 4 was utilized, followed by anti-goat histofine

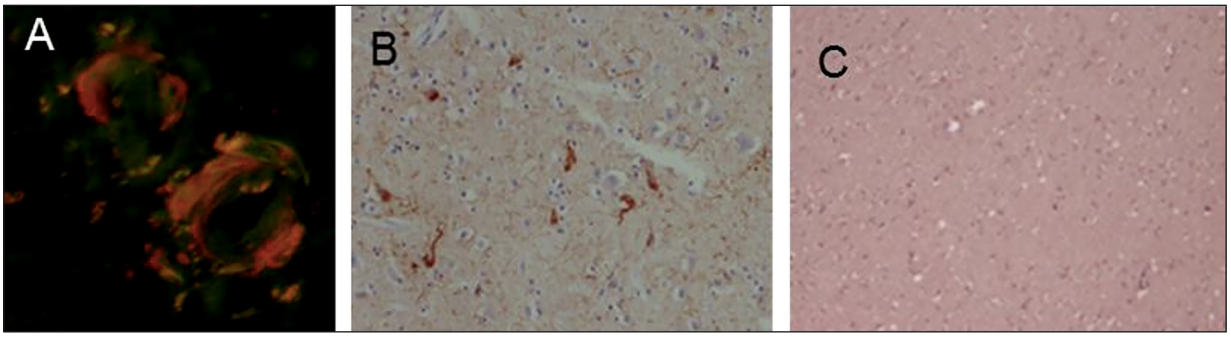

Figure 1. Stained cortical brain sections from stroke patients. Example of co-localisation within two adjacent microvessels of mCRP (FITC green) and beta-amyloid (TRITC-red) where the colour merges to orange yellow (**A**); the area is from within the stroke hemisphere in the stroke-affected cortex. **B,** Image shows strongly positive mCRP labelled neurons within a stroked brain region (DAB-brown; ×100). **C,** Contralateral hemisphere tissue showing no mCRP positivity within neurons or mivrovessels (DAB brown; ×40).

HRP and anti-goat CFL, for aquaporine4/CRP double staining. mCRP antigens were spotted using tyramide Cy3 (Perkin Elmer, Germany) as a development agent. On a Zeiss LSM700 confocal microscope, the slides will be seen with DAPI applied in ProLong® Gold Antifade reagent (Life Technologies). DAB staining was used for the control instances. Using the primary antibody as a negative control resulted in no aberrant cross-reactivity.

There were twelve C57BL/6J mice, six males each group in two separate groups of six. As explained by Slevin et al[6], stereotactic surgical procedures were used to administer 1.75 mg/mL mCRP into the CA1 area of the mouse hippocampus. Throughout the investigation, the weight and condition of every animal were closely examined. For gauging the general health of the mice, we routinely weighed and visually inspected each one.

The distribution of mCRP was examined through immunohistochemistry (mouse anti-human mCRP-specific antibodies 8C10). The mCRP-specific monoclonal antibody 8C10 was produced as demonstrated in the study by Schwedler et al[7].

Ethical Approval

Ethical approval was obtained by applying to the medical research council (MRC) at UK research and innovation website, details of the local approval are provided in Slevin et al[6], Mirra et al[8], Braak et al[9], and Montine et al[10].

The experiments were performed in accordance with European Union Council Directive 86/609/EEC on the protection of animals used for research and other scientific experiments and following the ARRIVE recommendations for the treatment of experimental animals. All the procedures for the study have been approved by the above indicated authorities[11].

Results

In the most recent lesions, yellowish gliotic tissue, cavitation, and tissue appeared soft, discolored, and with the presence of petechial hemorrhages was observed. However, the severity of the lesion did not affect neuronal staining, which can be seen in all our samples. mCRP in brain samples did not stain until six hours after the hemorrhage. After that, in hemorrhagic stroke areas, neurons showed strong staining in most of the cortical layers.

Necrotic tissue from the area of a recent ischemic event was littered with shrunken red blood cells, and the effects on the brain's tissue were observed (liquefactive necrosis, liquefied necrosis, reactive gliosis, ischemic cell death, perilesional neuronal lesions, and cortical vacuolation). Even mild vascular inflammation manifested in the form of petechiae, hemorrhages, and cerebral vessel vacuoles.

The infarcted tissue displayed structural integrity but contained large amounts of swelling and had neurons showing signs of apoptosis and vessel growth. The tissue just outside the infarct was well-structured, but it was extremely swollen and had deformed neurons (some of which had apoptosis), along with angiogenesis (Figure 2). Earlier, we proved that after delivering mCRP in the hippocampus of mice, the injected rodents displayed dementia-like cognitive and behavioral deficiencies, such as poor memory and control, alongside neurodegenerative cellular protein expression and morphology[3].

We observed a novel finding: those microvessels close to the injection location were strongly stained with mCRP only in the mice that had been injected with mCRP, indicating that this small blood vessel can spread throughout the brain. Furthermore, peripheral hypothalamic and cortical cells in the cytoplasm showed positive staining, but this phenomenon was not observed in the hippocampus or cerebral cortex in control mice.

Discussion

In this research, we found that ischemic/hemorrhagic events trigger the stress response in neurons, resulting in the expression of mCRP. Additionally, this implies that mCRP serves as a conduit for a post-ischemic/hemorrhagic stress response in the brain. Once the lesion is more advanced, inflammatory activation of the microglia occurs, potentially leading to local inflammation. Even though positive staining was more prevalent in advanced lesions, late degeneration and a host of other remote brain regions could be affected by mCRP.

A possible answer to the lesion's progression would be the macrophage or monocyte penetration of the capillary wall and subsequent local inflammation or microglial activation. Further, this positive staining was noticed in more advanced lesions and the macrophages/microglia. And in

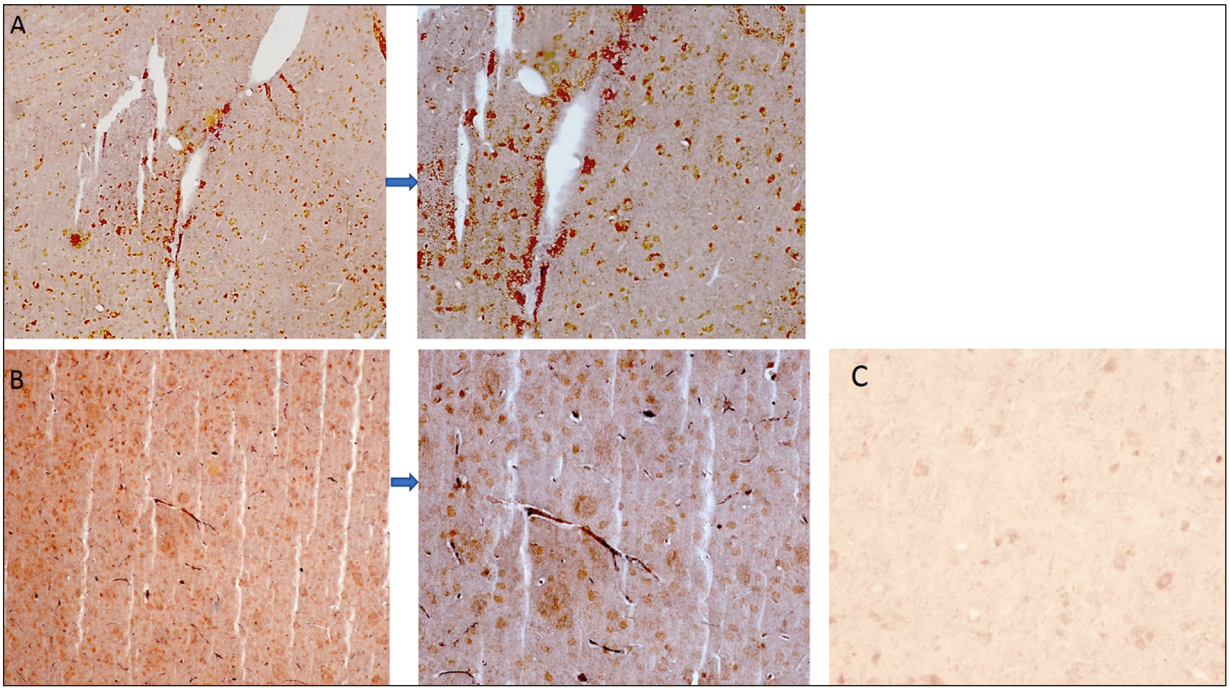

Figure 2. Distribution of mouse anti-human mCRP-specific antibodies 8C10 after stereotactic mCRP injection into the CA1 area of the mouse hippocampus. **A,** and **B,** CD34 positive cells (red; ×100) co-localizing with mCRP cortical positive regions (brown; ×100) indicating active endothelial cells facilitating tissue repair. **C,** Negative control with no primary antibody.

some cases, mCRP could even have consequences years later in people, potentially affecting several brain areas at once[12].

The number of microbleeds on CT/MRI was positively correlated with neuronal mCRP expression and the severity of the cognitive decline in dementia patients[13]. Cognitive impairment seemed to develop rapidly in survivors of ICH and the size and location of hematoma were found to be directly correlated with an increased risk of early dementia, whereas late-stage dementia did not show an apparent relationship with the severity of the injury[3,14].

Though the neuronal expression of mCRP is delayed in ICH cases, it is still indicative of its function as a mediator of stress, as well as neurodegeneration. Apart from having an association with inflammatory conditions, CRP levels have been found to increase the likelihood of developing neurodegenerative diseases, including dementia[15,16]. In recent years, mCRP has been hypothesized as a significant pathogenic component, with the potential to destabilize atherosclerosis and predispose patients to myocardial infarction[17].

The work of Li and Jia[12] supports our idea that the hypothalamus serves as a brain sensor that is coupled to peripheral inflammation. Specifically, they revealed that when hemorrhagic injuries were present in the parietal cortex, compensatory excitement was generated in the hypothalamus, which frequently resulted in tachyarrhythmia and sudden death.

Our mouse model and other research have shown that mCRP can be carried by existing microvascular structures to remote sites, including the hypothalamus, after local injection of mCRP or leaking in cases of hemorrhagic stroke.

Conclusions

mCRP can be found in the brain after a hemorrhagic stroke and is linked to the formation of the metabolic penumbra, as the microcirculatory system can carry it throughout the cortex and to the hypothalamus, which promotes damage over a large area *via* the induction of inflammation and degeneration of perivascular compartments.

Conflict of Interest

The Authors declare that they have no conflict of interests.

Ethics Approval

Ethical approval was obtained by applying to the medical research council (MRC) at UK research and innovation website. The experiments were performed in accordance with the EU Council Directive 86/609/EEC on the protection of animals used for research and other scientific experiments, and following the ARRIVE recom-mendations for the treatment of experimental animals.

Informed Consent

Not applicable.

Authors' Contribution

Conceptualization: AMA, FA, SAA; Design of the study: MS, WA, YM, BMA; Data collection: MA, MM, IA, RA; Compiling: WA, YM, BMA; Analysis and interpretation of the data: AMA. All the drafts were re-viewed by RSA, AMA, FA, SAA, MS, WA, YM, BMA, MA, MM, IA, RA.

Funding

The authors extend their appreciations to the deputyship for Research & Innovation, Ministry of Education in Saudi Arabia for funding this research work through the project number (IFP-2020-36).

ORCID ID

Ahmed M. Abdel-hadi: 0000-0002-1933-8197; Fuzail Ahmad: 0000-0002-1189-2206; Suliman A. Alsagaby: 0000-0002-2242-5638; Mark Slevin: 000-0003-3767-4861; Wael Alturaiki: 0000-0002-6947-7582; Yahya Madkhali: 0000-0001-7214-3543; Badr M. Aljarallah: 0000-0003-2169-9925; Mohammad Miraj: 0000-0001-8590-0531; Irshad Ahmad: 0000-0002-6012-9207; Nora Albaradie: 0000-0002-3230-6093; Reema Albaradie: 0000-0003-3109-8488.

References

1) Qureshi AI, Tuhrim S, Broderick JP, Batjer HH, Hondo H, Hanley DF. Spontaneous intracerebral hemorrhage. N Engl J Med 2001; 344: 1450-1460.
2) Thiele JR, Habersberger J, Braig D, Schmidt Y, Goerendt K, Maurer V, Bannasch H, Scheichl A, Woollard KJ, von Dobschütz E, Kolodgie F, Virmani R, Stark GB, Peter K, Eisenhardt SU. Dissociation of pentameric to monomeric C-reactive protein localizes and aggravates inflammation: in vivo proof of a powerful proinflammatory mechanism and a new anti-inflammatory strategy. Circulation 2014; 130: 35-50.
3) Slevin M, Matou S, Zeinolabediny Y, Corpas R, Weston R, Liu D, Boras E, Di Napoli M, Petcu E, Sarroca S, Popa-Wagner A, Love S, Font MA, Potempa LA, Al-Baradie R, Sanfeliu C, Revilla S, Badimon L, Krupinski J. Monomeric C-reactive protein--a key molecule driving development of Alz-heimer's disease associated with brain ischaemia? Sci Rep 2015; 5: 13281.
4) Slevin M, Liu D, Ferris G, Al-Hsinawi M, Al-Baradie R, Krupinski J. Expression of Monomeric C-Reactive Protein in Infarcted Brain Tissue from Patients with Alzheimer's Disease. Turk Patoloji Derg 2017; 33: 25-29.
5) Strang F, Scheichl A, Chen YC, Wang X, Htun NM, Bassler N, Eisenhardt SU, Habersberger J, Peter K. Amyloid plaques dissociate pentameric to monomeric C-reactive protein: a novel pathomechanism driving cortical inflammation in Alzheimer's disease? Brain Pathol 2012; 22: 337-346.
6) Slevin M, García-Lara E, Capitanescu B, Sanfeliu C, Zeinolabediny Y, AlBaradie R, Olah P, Guo B, Pirici D, Napoli MD, Popa-Wagner A. Monomeric C-Reactive Protein Aggravates Secondary Degen-eration after Intracerebral Haemorrhagic Stroke and May Function as a Sensor for Systemic Inflamma-tion. J Clin Med 2020; 9: 3053.
7) Slevin M, Matou-Nasri S, Turu M, Luque A, Rovira N, Badimon L, Boluda S, Potempa L, Sanfeliu C, de Vera N, Krupinski J. Modified C-reactive protein is expressed by stroke neovessels and is a potent ac-tivator of angiogenesis in vitro. Brain Pathol 2010; 20: 151-165.
8) Mirra JC, Heyman A, Mohs RC, Hughes JP, van Belle G, Fillenbaum G, Mellits ED, Clark C. The consortium to establish a registry for Alzheimer's disease (CERAD). Part II. Standardization of the neuropathologic assessment of Alzheimer's disease. Neurology 1997; 41: 479-486.
9) Braak H, Alafuzoff I, Arzberger T, Kretzschmar H, Del Tredici K. Staging of Alzheimer dis-ease-associated neurofibrillary pathology using paraffin sections and immunocytochemistry. Acta Neuropathol 2006; 112: 389-404.
10) Montine TJ, Phelps CH, Beach TG, Bigio EH, Cairns NJ, Dickson DW, Duyckaerts C, Frosch MP, Masliah E, Mirra SS, Nelson PT, Schneider JA, Thal DR, Trojanowski JQ, Vinters HV, Hyman BT; National Institute on Aging; Alzheimer's Association. National Institute on Aging-Alzheimer's Asso-ciation guidelines for the neuropathologic assessment of Alzheimer's disease: a practical approach. Acta Neuropathol 2012; 123: 1-11.
11) Al-Baradie RS, Pu S, Liu D, Zeinolabediny Y, Ferris G, Sanfeli C, Corpas R, Garcia-Lara E, Alsagaby SA, Alshehri BM, Abdel-Hadi AM, Ahmad F, Moatari P, Heidari N, Slevin M. Monomeric C-Reactive Protein Localized in the Cerebral Tissue of Damaged Vascular Brain Regions Is Associated With Neuro-Inflammation and Neurodegeneration-An Immunohistochemical Study. Front Immunol 2021; 12: 644213.
12) Li F, Jia Y. Cortical infarction of the right parietal lobe and neurogenic heart disease: A report of three cases. Neural Regen Res 2012; 7: 943-947.
13) Martini S, Testai FD, Woo D, Elkind MSV. Systemic inflammatory response syndrome, infection,

and outcome in intracerebral hemorrhage. Neurol Neuroimmunol Neuroinflamm 2017; 5: e428.

14) Biffi A, Bailey D, Anderson CD, Ayres AM, Gurol EM, Greenberg SM, Rosand J, Viswanathan A. Risk Factors Associated With Early vs Delayed Dementia After Intracerebral Hemorrhage. JAMA Neurol 2016; 73: 969-976.

15) Rasmussen MK, Mestre H, Nedergaard M. The glymphatic pathway in neurological disorders. Lancet Neurol 2018; 17: 1016-1024.

16) Romero JR, Beiser A, Himali JJ, Shoamanesh A, DeCarli C, Seshadri S. Cerebral microbleeds and risk of incident dementia: the Framingham Heart Study. Neurobiol Aging 2017; 54: 94-99.

17) Stumpf C, Sheriff A, Zimmermann S, Schaefauer L, Schlundt C, Raaz D, Garlichs CD, Achenbach S. C-reactive protein levels predict systolic heart failure and outcome in patients with first ST-elevation myocardial infarction treated with coronary angioplasty. Arch Med Sci 2017; 13: 1086-1093.